

LETTER TO JMG

Acrocapitofemoral dysplasia: an autosomal recessive skeletal dysplasia with cone shaped epiphyses in the hands and hips

G R Mortier, P P G Kramer, A Giedion, F A Beemer

J Med Genet 2003;**40**:201–207

Genetic disorders of the skeleton or skeletal dysplasias are a clinically diverse and genetically heterogeneous group of connective tissue disorders affecting skeletal morphogenesis and development.^{1–4} More than 200 different entities have been described.⁵ Despite the growing availability of molecular testing for several of these disorders, the diagnosis of a skeletal dysplasia still relies primarily on a thorough clinical and radiographic study of the patient.⁶ Some particular radiographic signs can be very helpful in establishing the diagnosis. One such example is the presence of cone shaped epiphyses.⁷ In most instances, cone shaped epiphyses represent the initial stage of premature epimetaphyseal fusion resulting in growth arrest and shortening of the bone involved. Analysis of the site and shape of cone shaped epiphyses, in particular of the phalanges, can be helpful in the diagnosis of skeletal dysplasias.^{8–10}

Based on the observation of four patients, we delineate a new skeletal dysplasia with autosomal recessive inheritance. Because all cases show cone shaped epiphyses in the hands and a radiographically characteristic involvement of the proximal femoral epiphyses, we propose naming this condition acrocapitofemoral dysplasia.

CASE REPORTS

Patient 1

Patient 1 was referred at the age of 9.5 years with the tentative diagnosis of hypochondroplasia. She was born at 34 weeks' gestation with a birth weight of 2470 g (50th centile) and length of 47 cm (50th–90th centile). The pregnancy was

uncomplicated and the delivery uneventful. Around the age of 7 years, short stature was noted. She had normal psychomotor development but experienced emotional problems related to her short stature. The parents are healthy but consanguineous

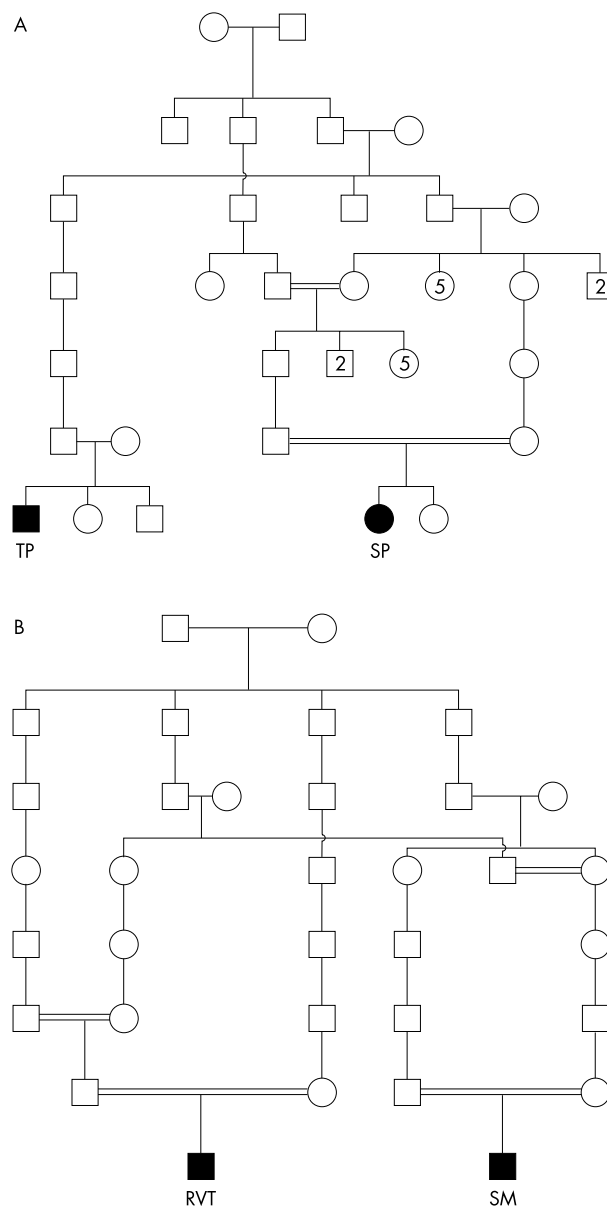


Figure 1 Pedigrees of (A) the Belgian and (B) the Dutch families. Filled symbols indicate the affected subjects.

Key points

- We delineate the radiographic and clinical features of four children who appear to have a hitherto undescribed skeletal dysplasia.
- The disorder shows autosomal recessive inheritance.
- The clinical phenotype is characterised by short stature with brachydactyly, a narrow thorax, and a relatively large head.
- Cone shaped epiphyses are present in the hands and to a variable degree in the shoulders, knees, and ankles. Progressive closure of the growth plate around the cone shaped epiphyses early on in childhood results in short tubular bones.
- In the hips, premature epimetaphyseal fusion of the proximal femoral epiphysis results in an egg shaped femoral head and very short femoral neck.
- The most distinguishing and constant radiographic changes in the hands and hips prompted us to name the disorder acrocapitofemoral dysplasia.

Table 1 Clinical and radiographic features of the four patients and the case reported by Hoeffel *et al*¹²

	Patient 1	Patient 2	Patient 3	Patient 4	Case of Hoeffel <i>et al</i> ¹²
Stature (age)	- 3.5 SD (9.5 years)	- 2.3 SD (9.5 years)	- 3 SD (7 years)	- 7.6 SD (9 years)	- 7 SD (12 years)
OFC	3th-50th centile	50th-75th centile	90th centile	>98th centile	?
Short limbs	+	+	++	+++	+++
Brachydactyly	Yes	Yes	Yes	Yes	Yes
Deformities	No	No	No	Genu varum	Genu varum
Thorax	Narrow	Normal	P excavatum	P carinatum	?
Hands (age)	(at 9.5 y)	(at 9.5 y)	(at 3 8/12 y)	(at 11 y)	(at 12 y)
CSE in thumbs	Yes	Yes	Yes	Yes	?
CSE in m & d phal	Yes	Yes	Yes	Yes	Yes
CSE in p phal	No	No	Yes	Yes	No
CSE in metacarp	No (thumb only)	No (thumb only)	Yes	Yes	Yes
Carpal bone age	Retarded	Retarded	Retarded	Retarded	Retarded
Pelvis (age)	(at 9.5 y)	(at 9.5 y)	(at 3 8/12 y)	(at 10 y)	(at 8 y)
Iliac wings	N	N	Short, flared	Short, flared	N
Acetabular roofs	N	N	Flat, wide	N	Oblique
Coxa vara	No	Yes	Yes	Yes	Yes
Prox fem physis	Fused	Fused	Fused	Fused	Fused
Femoral head	Egg shaped	Egg shaped	Egg shaped	Egg shaped	Egg shaped
Femoral neck	Short	Short	Short	Short	Short
Femoral "collar"	Yes	Yes	Yes	Yes	Yes
Upper limbs	(at 9.5 y)	(at 9.5 y)	(at 7 y)	(at 9 y)	(at 8 y)
Humeral head	N	N	Varus deformity	CSE	Varus deformity
Shortening H/U/R	+	+	++	+++	?
Lower limbs	(at 9.5 y)	(at 11 y)	(at 5 y)	(at 11 y)	(at 12 y)
Dist fem epiph	Large	Large	Large	Large	?
Prox tib epiph	Reduced width	Reduced width	Reduced width	CSE	CSE
Dist tib physis	Early closure	Early closure	CSE	CSE	CSE
Prox part fibula	Mild overgrowth	Mild overgrowth	Overgrowth	Overgrowth	Overgrowth
Short tibia	+	+	++	+++	++
Tibia vara	No	No	Yes	Yes	Yes

OFC: occipitofrontal (head) circumference; P: pectus; CSE: cone shaped epiphyses; d/m/p phal: distal/middle/proximal phalanges; metacarp: metacarpals; fem/tib: femoral/tibial; H/U/R: humerus/ulna/radius; epiph: epiphysis; N: normal.

(fig 1A). The father measures 166 cm and the mother 163 cm. A younger sister is also healthy and has a normal height. Physical examination at the age of 9 years 6 months showed short stature with height 1.15 m (-3.5 SD, height age 5 years 10 months), span 107 cm, upper segment/lower segment 1.25 (+2.4 SD), weight 25.4 kg (10th-25th centile), and head circumference 51 cm (10th-25th centile). Dysmorphic craniofacial features were absent (fig 2A). The thorax was slightly narrow and a lumbar hyperlordosis was noted. The hands and fingers (especially the thumbs) were short with small and broad nails. Normal mobility at the joints was noted. The gait was normal. A radiographic survey at the age of 9.5 years showed abnormalities mainly in the hands and hips. Strikingly, there were very short middle and distal phalanges with some traces of previous cone shaped epiphyses (fig 3C). Except for distal phalanges II and V, closure of the growth plates was nearly complete in all distal and middle phalanges. The proximal phalanges and metacarpals of digits II to V were only slightly shortened. The proximal phalanx and metacarpal of both thumbs were moderately shortened with cone shaped epiphyses. In contrast to the advanced maturation of the short tubular bones, the carpal bone age was 6 years 10 months. The pelvis was remarkable by the bilateral presence of a dysplastic (egg shaped) femoral head and very short (almost non-existent) femoral neck with complete epimetaphyseal fusion (fig 4C). At the medial side of the femoral neck a distinct bony collar was visible. Shortening of the long tubular bones in the upper and lower limbs was quite mild. The head of the humerus and the capitulum radii were slightly enlarged. Mild enlargement of the distal femoral epiphyses and reduced width of the proximal tibial epiphyses with irregularities in the adjacent medial portion of the metaphyses were observed in the knees. Mild fibular overgrowth was noted proximally. Partial

closure of the distal tibial growth plate was present. The thorax was normal with mild metaphyseal cupping of the ribs. The vertebral bodies were slightly ovoid with anterior notching.

Patient 2

Patient 2 is the oldest child of healthy parents and related to patient 1 through his father (fig 1A). The family is of Belgian origin. The father measures 172 cm and the mother 156 cm. He was born at term with a birth weight of 3000 g and length of 52 cm. The pregnancy and delivery were uncomplicated. He had normal psychomotor development. Because of complaints of easy fatigue after exercise, he was referred aged 9.5 years with the tentative diagnosis of multiple epiphyseal dysplasia. Physical examination at the age of 9.5 years showed short stature with height 121.5 cm (-2.3 SD, height age 6 years 7 months), span 118.5 cm, upper segment/lower segment 1.19 (50th-75th centile), weight 26.5 kg (3th-25th centile), and head circumference 53.5 cm (50th-75th centile). There were no dysmorphic craniofacial features (fig 2B). Lumbar hyperlordosis was noted. The hands and fingers (especially the thumbs) were short with small and broad nails. Restricted or increased mobility at the joints was not observed. The gait was normal. Skeletal survey at the age of 9.5 years showed similar abnormalities to those of patient 1. Hand radiographs were abnormal with very short middle phalanges. All middle phalanges showed cone shaped epiphyses with almost complete epimetaphyseal fusion. The distal phalanges II-V were also short with partially fused cone shaped epiphyses. The proximal phalanx and metacarpal of both thumbs were moderately shortened with cone shaped epiphyses. Shortening of the proximal phalanges and metacarpals II-V was very mild. The carpal bone age was 6 years. The hips were similar to patient 1 with coxa vara deformity, dysplastic (egg shaped)

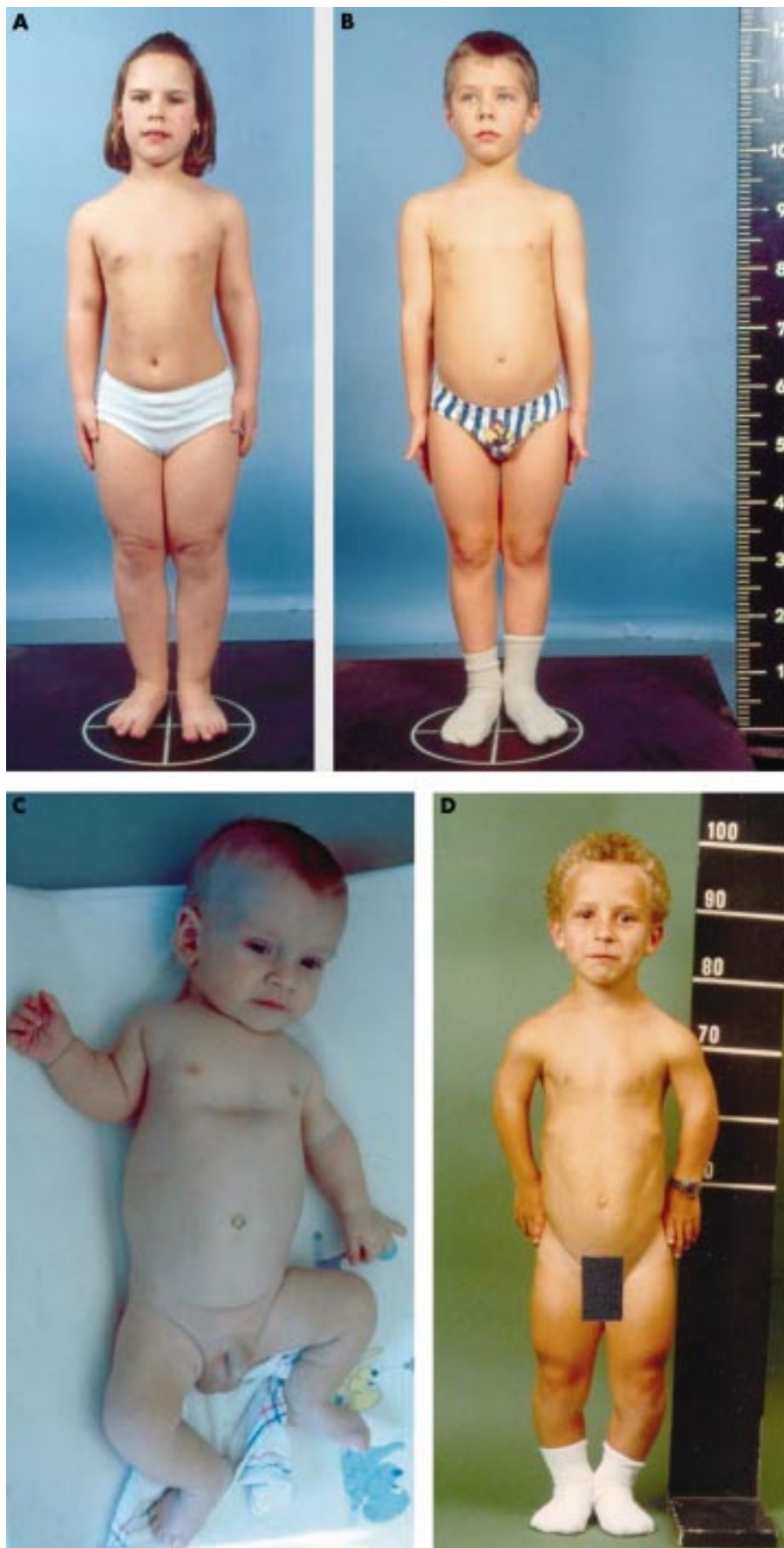

Figure 2 Photographs of (A) patient 1 aged 10.5 years, (B) patient 2 aged 10 years, (C) patient 3 aged 4 months, and (D) patient 4 aged 9 years, showing variable degrees of short limb dwarfism.

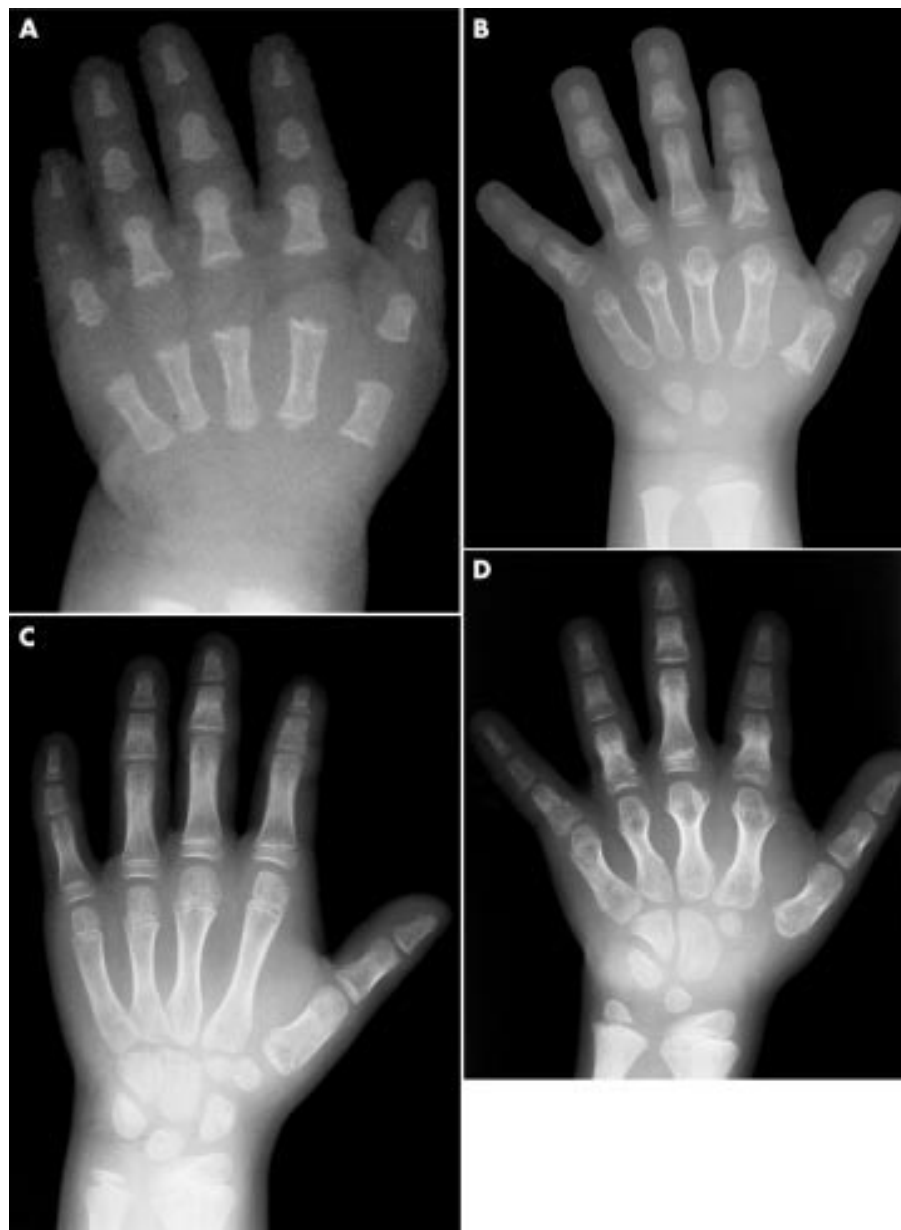


Figure 3 Radiographs of the left hand. (A) Patient 4 aged 4 months. The metacarpals and proximal and middle phalanges are short with mild cupping of the metaphyses and attached small epiphyseal ossification centres. Note the pseudoepiphysis at the base of the second metacarpal and hypoplasia of the fifth middle phalanx. Retarded carpal bone age. (B) Patient 3 aged 3.5 years. Cone shaped epiphyses of all tubular bones (except proximal phalanges III and IV) and retarded carpal bone age. Presence of pseudoepiphysis at the base of the second metacarpal. (C) Patient 1 aged 9.5 years. Cone shaped epiphyses are present in the thumbs and the middle and distal phalanges of digits II-V. The shortening is most pronounced in the middle and distal phalanges. Retarded carpal bone age. (D) Patient 4 aged 11 years. With the exception of the third proximal phalanx, all tubular bones are severely shortened. Some still show cone shaped epiphyses, in others the epimetaphyseal fusion is complete. Note the fused tear drop metacarpal epiphyses. Retarded carpal bone age.

femoral heads, and severe hypoplasia of the femoral necks owing to premature epimetaphyseal fusion. The long tubular bones of the upper and lower limbs were only slightly shortened. At the knees, similar changes were observed to those in patient 1. The thorax was normal with mild metaphyseal cupping of the ribs. The vertebral bodies showed anterior notching. Premature closure of the tibial growth plate was observed at the ankles at the age of 11 years.

Patient 3

Patient 3 (SM) presented at the age of 4 months with short stature, short arms, and pectus excavatum (fig 2C). Infancy was complicated by episodes of tachypnoea from birth onwards and recurrent respiratory infections. Birth weight at

term was 3800 g and length 51 cm. The parents are consanguineous (fig 1B). The father measures 185 cm and the mother 163 cm. Physical examination at the age of 7 years showed short stature with a height of 109 cm (-3 SD, height age 4.5 years), span of 94.3 cm, and head circumference of 53.5 cm (90th centile). The short limbs with short hands and pectus excavatum were striking. Radiographs of the skeleton were taken at various ages. At the age of 22 months, the hands showed shortening of all tubular bones. With the exception of proximal phalanges III and IV, cone shaped epiphyses of type 19, 25, and 28 were present in all of them. Characteristic were the “tear drop shaped” cones of the markedly shortened metacarpals. At the base of the second metacarpal, a pseudoepiphysis was present. The pelvis at the same age was

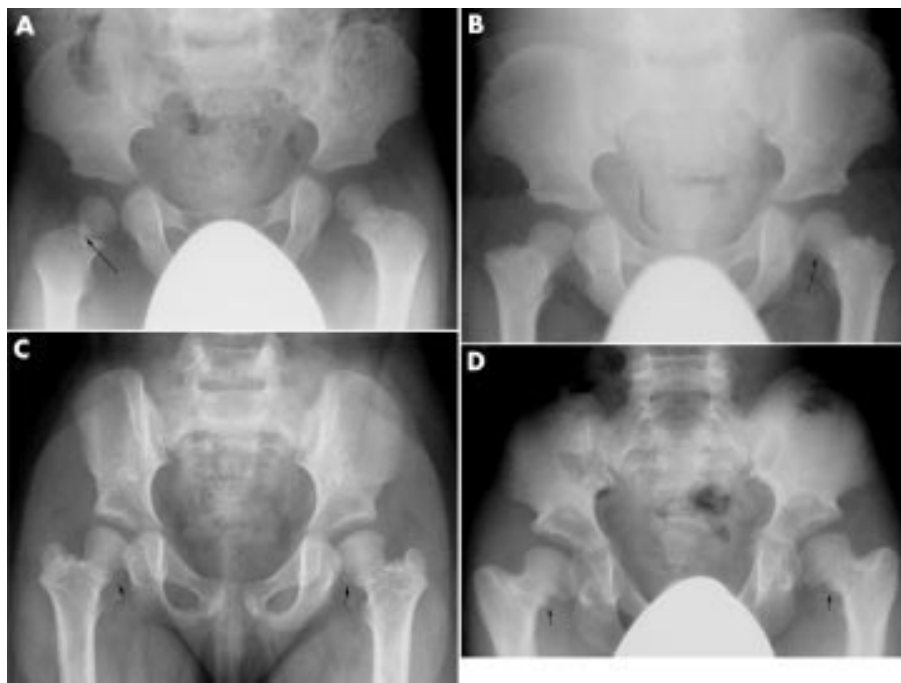


Figure 4 Radiographs of the pelvis. (A) Patient 3 aged 22 months. The pelvis is characterised by short and flared iliac wings. The point of the tear drop shaped femoral epiphyses is buried in the metaphysis of the femoral neck (most typical on the right side, arrow). (B) Patient 3 aged 3 years 8 months. Complete fusion of the proximal femoral growth plate. Formation of the “collar” on the left femoral neck (arrow). (C) Patient 1 aged 6 years. Coxa vara with egg shaped femoral head and very short femoral neck. Note “collar” on both femoral necks (arrows). (D) Patient 4 aged 10 years. Some flaring of the iliac wings. Coxa vara with egg shaped femoral head and very short femoral neck with “collar” (arrow).

characterised by short and flared iliac wings with serration of the iliac crest and flat acetabular roofs. The proximal femoral epiphyses were almost rounded and well developed but pointed (tear drop shaped) towards the metaphysis showing a central indentation (fig 4A). At the age of 3 years 8 months, epimetaphyseal fusion at the hips was completed (fig 4B). The same process of progressive closure of the physis around the cone shaped epiphyses was observed in the hands (fig 3B). The long tubular bones in the upper and lower limbs were also short. The humerus was broad with varus deformity of the neck. The diaphysis of the radius was bowed. The knees at the age of 5 years showed large distal femoral epiphyses, varus deformity of the tibia, irregular proximal tibial metaphyses, and proximal overgrowth of the fibula. At the same age, cone shaped distal tibial epiphyses were observed. Radiographs of the spine showed mild thoracolumbar scoliosis (aged 5 years) and moderately ovoid vertebral bodies with anterior and posterior notching (fig 5A). Radiographs of the thorax showed signs of a funnel chest.

Patient 4

Patient 4 was born at term after an uncomplicated pregnancy with a birth weight of 3490 g and length of 45 cm. The parents are consanguineous and belong to the same inbred Dutch community as patient 3 (fig 1B). Both parents measure 157 cm. The boy had normal psychomotor development. Clinical examination at the age of 9 years 3 months showed macrocephaly and short limb dwarfism (fig 2D). Height was 97.5 cm (– 7.6 SD, height age 3 years 3 months), span 80 cm, and head circumference 55 cm (98th centile 54.5 cm). There were no craniofacial dysmorphic features. Pectus carinatum with flaring of the lower ribs was noted. Lumbar hyperlordosis and genua vara were also observed. His adult height is 114 cm (– 8.6 SD). Skeletal radiographs at various ages were available, also illustrating the early radiographic abnormalities of the disorder. At the age of 4 months, the hands showed shortening of all tubular bones with the exception of the

distal phalanges (fig 3A). The metaphyses of metacarpals II-V were slightly cupped with a small attached epiphysis (most apparent in metacarpals II and III). A small epiphyseal ossification centre was also attached to the metaphyses of middle and distal phalanges and to the tubular bones of the thumbs. The fifth middle phalanx was only represented by a small and round ossification centre. At the base of the second metacarpal, a pseudoepiphysis was present. The pelvis at birth was normal but at the age of 2 years was characterised by short, flared iliac wings with serration of the iliac crest and rounded, tear drop shaped femoral epiphyses, again pointed towards a minute central indentation of the irregular metaphysis. The knees at 2 years showed rather voluminous femoral epiphyses in contrast to the rather small tibial epiphyses. At the same age, additional findings included narrow thorax with short ribs, mild dextroconvex lumbar scoliosis, and slightly ovoid vertebral bodies with anterior notching. A skeletal survey between the ages of 9 and 11 years showed short tubular bones in the upper and lower limbs. The diaphysis of the humerus was very short with “coning” of the proximal rounded epiphysis towards the irregular and cupped metaphysis (fig 5B). The hands at the age of 11 years showed premature physal closure of almost all markedly shortened tubular bones with vestiges of previous cone shaped epiphyses (fig 3D). Typical cone shaped epiphyses of type 28 were still present in the proximal phalanges II and IV. The dissociated carpal bone age corresponded to a chronological age of 6-8 years. The hips at 10 years of age showed short and flared iliac wings, coxa vara with egg shaped femoral heads, and shortened femoral necks as the result of premature epimetaphyseal fusion (fig 4D). As in the other patients, a small bony protrusion (“collar”) was seen at the medial border of the femoral neck proximal to the trochanter minor. The knees at 11 years were characterised by large femoral epiphyses, a suggestion of previous cone shaped tibial epiphyses with almost complete closure of the physis, varus deformity of the shortened tibiae and, in spite of the already closed physis, a remarkable proximal overgrowth of

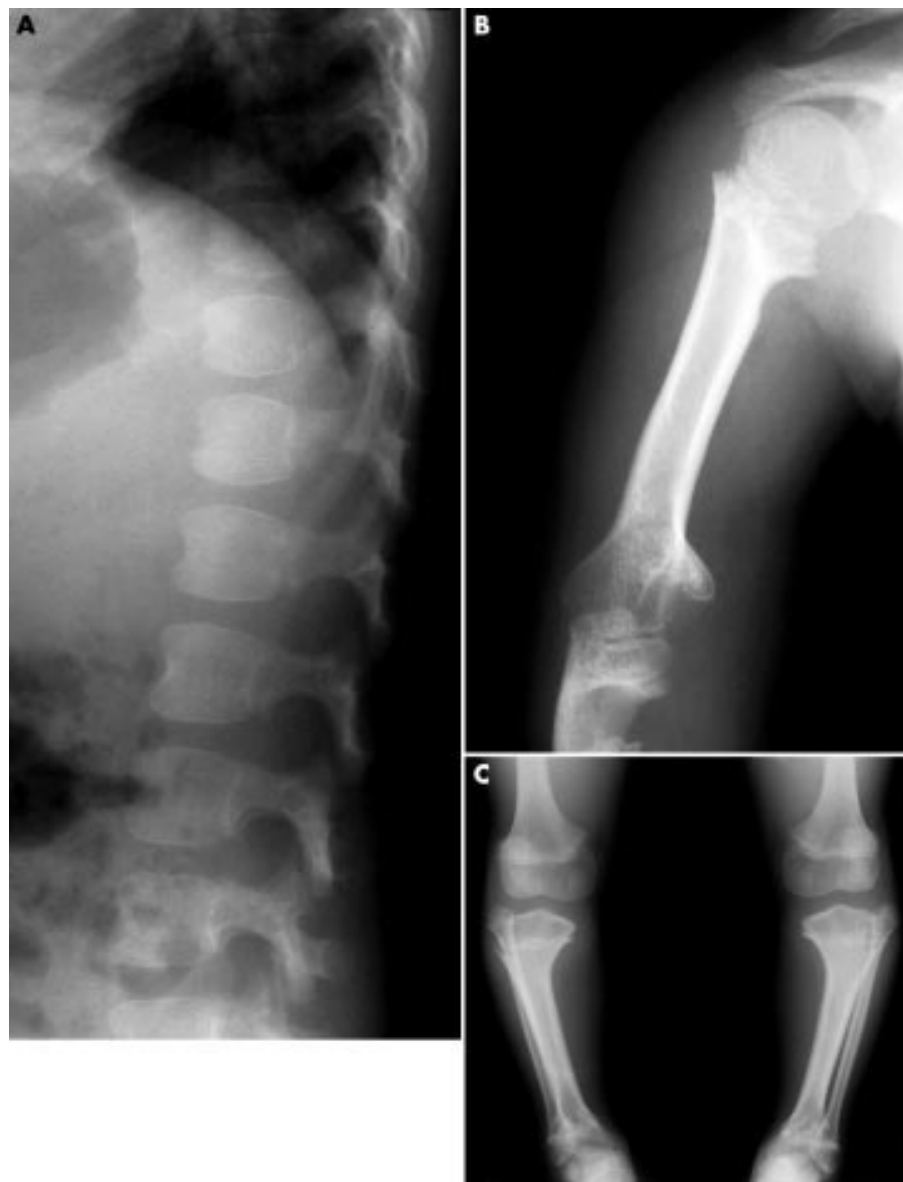

Figure 5 Radiographs of the spine and upper/lower limbs. (A) Patient 3 aged 3.5 years. Lateral view of the thoracolumbar spine showing ovoid vertebral bodies with anterior notching and mild posterior scalloping. (B) Patient 4 aged 9 years. Severely shortened left humerus. Blown up egg shaped humeral epiphysis buried in a cupped and irregular metaphysis. (C) Patient 4 aged 11 years. The distal femoral epiphyses are voluminous. Varus deformity of the tibia with proximal and distal premature epimetaphyseal fusion, most likely the result of cone shaped epiphyses. Proximal overgrowth of the fibulae.

the fibulae (fig 5C). The distal tibial epiphyses were enlarged and cone shaped with complete closure of the physis.

DISCUSSION

We report the radiographic and clinical features of four children who appear to have a hitherto undescribed skeletal dysplasia. The clinical phenotype is characterised by short stature of variable severity with postnatal onset in three of the four patients studied (fig 2). All four cases show short limbs with brachydactyly (table 1). The height, measured at various ages, ranges from 2.3 to 8.6 SD below the mean. The head circumference is relatively large. The thorax is rather narrow with pectus deformities in 2/4 patients. Only patient 4 has genua vara. The affected subjects do not exhibit associated congenital anomalies and are of normal intelligence.

The most striking and constant radiographic abnormalities are observed in the tubular bones of the hands and in the proximal part of the femur (figs 3 and 4). Here, cone shaped

epiphyses or a similar epiphyseal configuration with premature epimetaphyseal fusion result in shortening of the skeletal components involved. Cone shaped epiphyses are also present to a variable extent at the shoulders, knees, and ankles. These cone shaped epiphyses appear early in childhood and disappear with the premature fusion of the growth plate. The spine is only mildly involved with a slightly ovoid appearance of the vertebral bodies.

The hips present the most characteristic radiographic appearance of this condition. The proximal femoral epiphysis develops, around the age of 2 years, a small, thorn-like outgrowth pointing to the centre of the femoral neck, resembling a tear drop but also, to some extent, reminiscent of a cone shaped epiphysis (fig 4A). This is followed by a premature epimetaphyseal fusion resulting, between the age of 3 to 5 years, in an egg shaped femoral head attached to a very short femoral neck with a collar-like, small bony outgrowth (fig 4B-D).

In the hands, cone shaped epiphyses are observed in the middle and distal phalanges and thumbs (fig 3). Patients 3 and 4 in addition show cone shaped epiphyses in the proximal phalanges and metacarpals. Interestingly, the cone shaped epiphyses in the metacarpals are also tear drop shaped. Progressive closure of the growth plate around the cone shaped epiphyses results in short tubular bones. The shortening is most pronounced in the middle phalanges. As in the hips, the cone shaped epiphyses appear early in infancy.

Cone shaped epiphyses of the phalanges and metacarpals are observed in a large number of skeletal dysplasias, in particular in the group of acromelic and acromesomelic dysplasias.³⁻⁵ In some of them, an almost diagnostic type of "cone" is present, for example, the type 12 cone in trichorhinophalangeal dysplasia type I or the "flattened half moon type" cone in cartilage hair hypoplasia.¹⁰ In our cases, very early closure of the physis hampers the precise identification of the cone shaped epiphyses. Only in patient 3 types 19, 25, 28 and in patient 4 types 28 can be seen.

Premature fusion of the proximal femoral growth plate is rarely seen in skeletal dysplasias. It can be observed in "spondylo-meta-epiphyseal dysplasia, short limb-abnormal calcification type", an otherwise entirely different condition.¹¹ To our knowledge, the association of cone shaped epiphyses in the hands and premature epimetaphyseal fusion of the capital femoral epiphyses has only been reported once in a 12 year old boy by Hoeffel *et al*¹² (table 1). In this case, cone shaped epiphyses were also present at the shoulders, knees, and ankles. However, the middle phalanges showed remnants of type 12 cone shaped epiphyses which were not observed in our four patients.

Acrocapitofemoral dysplasia should not be confused with hypochondroplasia and asphyxiating thoracic dysplasia. The differential diagnosis with hypochondroplasia should not be problematical in childhood since premature closure of the growth plate is not observed in hypochondroplasia. However, in adulthood, when the growth plate is normally closed, the condition may resemble hypochondroplasia because of the short tubular bones in the hands and the short femoral necks. Normal shape of the femoral heads and interpedicular narrowing of the lumbar vertebral bodies are the most important features that will distinguish hypochondroplasia from acrocapitofemoral dysplasia in an adult patient. A narrow thorax and cone shaped epiphyses of the phalanges are features of asphyxiating thoracic dysplasia (Jeune dysplasia). However, in the latter condition, cone shaped epiphyses at other sites of the skeleton are not observed. Also, the pelvis in Jeune dysplasia usually shows the characteristic trident acetabular roof which is not found in acrocapitofemoral dysplasia.

The pedigrees of both families are very suggestive of a genetic defect with autosomal recessive inheritance (fig 1). The radiographic evidence of fusion of the growth plate early in childhood at several sites of the skeleton may suggest that the gene involved in this disorder is important in maintaining

the growth plate in an active stage before closure at puberty. Using a homozygosity mapping strategy in both families, a genome wide search can be performed in order to identify the gene responsible for this dysplasia.

ACKNOWLEDGEMENTS

We thank the families for their interest and cooperation. Excellent technical assistance in preparing the radiographic illustrations was provided by G Dermaut and M L Duyts. We are grateful to J Spranger and K Kozlowski for their comments on the radiographs of patient 4 several years ago. This study was supported in part by the Fund for Scientific Research, Flanders with a mandate "fundamental clinical research" to G Mortier and also by the Fifth Framework of the specific research and technological development programme "Quality of Life and Management of Living Resources" of the European Commission (Contract No QLG1-CT-2001-02188) to GM.

.....

Authors' affiliations

G R Mortier, Department of Medical Genetics, Ghent University Hospital, Ghent, Belgium

P P G Kramer, Department of Radiology, University Medical Centre, Utrecht, The Netherlands

A Giedion, Department of Radiology, Children's Hospital, Zürich, Switzerland

F A Beemer, Department of Medical Genetics, Division of Biomedical Genetics, University Medical Centre, Utrecht, The Netherlands

Correspondence to: Dr G Mortier, Department of Medical Genetics, Ghent University Hospital, De Pintelaan 185, B-9000 Ghent, Belgium; geert.mortier@rug.ac.be

REFERENCES

- Horton WA, Hecht JT. The chondrodysplasias. In: Royce PM, Steinmann B, eds. *Connective tissue and its heritable disorders*. New York: Wiley-Liss, 1993:641-75.
- Rimoin DL, Lachman RS. Genetic disorders of the osseous skeleton. In: Beighton P, ed. *McKusick's heritable disorders of connective tissue*. St. Louis: Mosby-Year Book, 1993:557-689.
- Maroteaux P, ed. *Les maladies osseuses de l'enfant*. Paris: Flammarion Médecine-Sciences, 1995.
- Lachman RS. Skeletal dysplasias. In: Taybi H, Lachman RS, eds. *Radiology of syndromes, metabolic disorders, and skeletal dysplasias*. St Louis: Mosby-Year Book, 1996:745-951.
- Hall CM, for the International Nomenclature Group on Constitutional Disorders of Bone. International nosology and classification of constitutional disorders of bone. *Am J Med Genet* 2002;**113**:65-77.
- Mortier GR. The diagnosis of skeletal dysplasias: a multidisciplinary approach. *Eur J Radiol* 2001;**40**:161-7.
- Giedion A. Cone-shaped epiphyses. *Ann Radiol* 1965;**8**:135-45.
- Giedion A. Cone-shaped epiphyses of the hands and their diagnostic value. *Ann Radiol* 1967;**10**:322-9.
- Giedion A. Phalangeal cone-shaped epiphyses of the hands and chronic renal disease: the conorenal syndromes. *Pediatr Radiol* 1979;**8**:32-8.
- Giedion A. Phalangeal cone-shaped epiphyses of the hand: their natural history, diagnostic sensitivity, and specificity in cartilage hair hypoplasia and the trichorhinophalangeal syndromes I and II. *Pediatr Radiol* 1998;**28**:751-8.
- Langer LO, Wolfson BJ, Scott CI, Reid CS, Schidlow DV, Millar EA, Borns PF, Lubicky JP, Carpenter BLM. Further delineation of spondylo-meta-epiphyseal dysplasia, short limb-abnormal calcification type, with emphasis on diagnostic features. *Am J Med Genet* 1993;**45**:488-500.
- Hoeffel JC, Didier F, Chantereau D, Medoc JM, Muller JP. Metaphyseal dyschondroplasia with cone-shaped epiphyses. *Br J Radiol* 1987;**60**:707-10.